

## Case Report

# Giant Polypoid Gastric Heterotopia of the Jejunum Presenting with Intermittent Intussusception

PHILIP A. OMOTOSHO, MD, HEIKE VARNHOLT, MD, MICHAEL V. TIRABASSI, MD,  
RAJEEV PRASAD, MD, and KEVIN P. MORIARTY, MD

### ABSTRACT

**We report the case of a 17-year-old female with symptoms of intermittent small bowel obstruction. Computed tomography scan of the abdomen revealed an intussusception. The patient underwent a laparoscopic-assisted resection of the mass, which proved to be gastric heterotopia of the jejunum. We report on the case, discuss the surgical approach, and review the pertinent literature.**

### INTRODUCTION

**G**ASTRIC HETEROTOPIA MANIFESTING as an obstructing mass in the jejunum is uncommon. Heterotopic gastric tissue is found in association with other entities within the small bowel, such as Meckel's diverticulum or duplications. The biology of this entity has been characterized as hyperplasia of primitive gut epithelium over time. Presenting symptoms range from mild dyspepsia to massive gastrointestinal (GI) bleeding and intestinal perforation.<sup>6</sup> We report on a case associated with intussusception which we treated with a minimally invasive approach.

### CASE REPORT

A 17-year-old otherwise healthy female presented to her pediatrician's office with a 6-month history of gastroesophageal reflux–like symptoms, epigastric pain, and occasional bilious vomiting. Medical therapy aimed at the reflux symptoms was unsuccessful. Esophagogastro-

duodenoscopy, followed by an upper GI series with small bowel followthrough, were obtained upon gastroenterology consultation. These studies were both negative. The patient continued to be symptomatic and was referred for surgical evaluation. A computed tomography (CT) scan of the abdomen revealed a small bowel intussusception (Fig. 1). The administered oral contrast was visualized in the distal small bowel and colon on delayed images, suggesting an intermittent process.

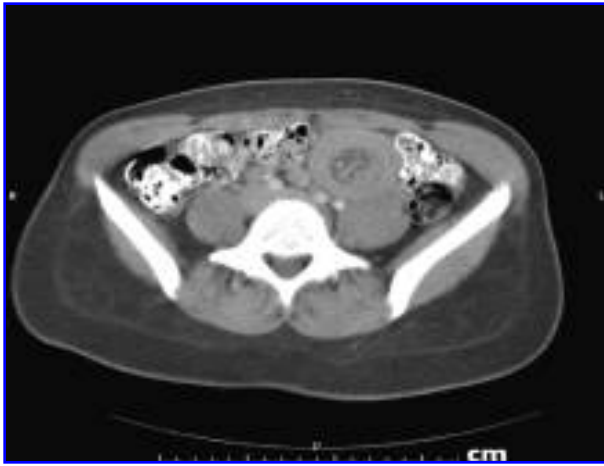#### *Surgical technique*

We used a three-port technique: a 12-mm supraumbilical Hasson port, a 5-mm port in the right upper quadrant, and a 5-mm port in the left lateral abdomen at the level of the umbilicus. The entire small bowel was inspected and run from the ileocecal valve to the ligament of Treitz. A dilated and thickened segment of proximal jejunum, with a clear transition point approximately 60 cm from the ligament of Treitz, was identified. The small bowel was delivered through a Tan-Bianchi circumum-

---

Baystate Children's Hospital, Tufts University School of Medicine, Springfield, Massachusetts.

Presented as a poster at the 15th Annual International Pediatric Endosurgery Group Congress of Endosurgery in Children, Dallas, Texas, April 26–29, 2006.

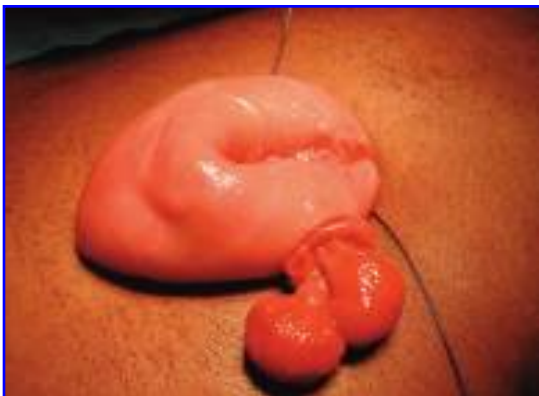

**FIG. 1.** Computed tomography scan demonstrating intussusception.

bilical incision. Proximal to the transition point there was a palpable intraluminal mass as the lead point (Fig. 2). An enterotomy was made distal to the palpable mass to expose a single bi-lobed polyp on the antimesenteric border. The polyp was resected using an endo-GIA stapler and the enterotomy was closed. The remainder of the small intestine was normal. Histologic examination revealed a giant polypoid gastric heterotopia of the jejunum without atypia (Fig. 3). The patient had an uneventful recovery and remained asymptomatic at 6-month follow-up.

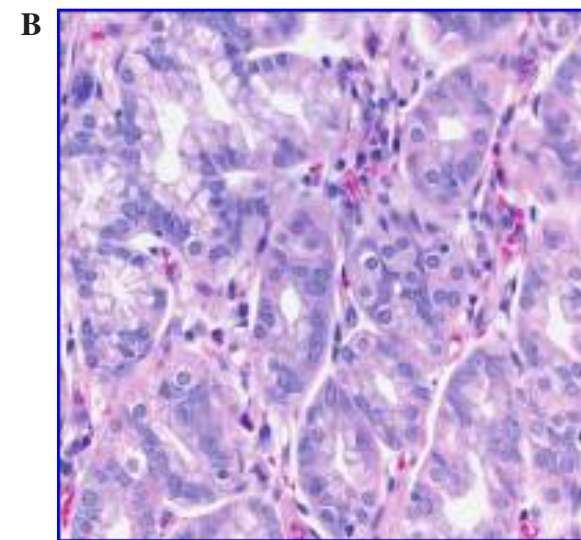
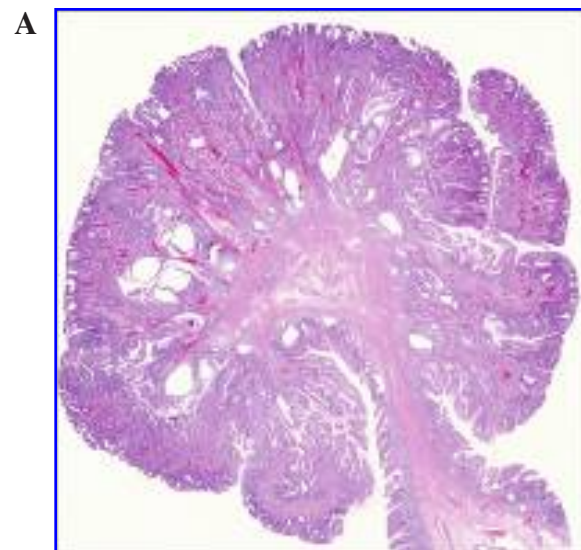
### DISCUSSION

Gastric heterotopia presenting as a tumorous mass in the jejunum is uncommon.<sup>1</sup> Ectopic gastric mucosa is a well-recognized phenomenon in association with Meckel's diverticulum in the distal small intestine and



**FIG. 2.** A single bi-lobed jejunal polyp, which was the lead point for the intussusception.

with other anomalies, such as duplications.<sup>3</sup> Other infrequently documented locations of ectopic gastric mucosa in the GI tract include the oral mucosa, upper esophagus, duodenum, and the biliary tract. It is thought that these lesions arise from the primitive gut epithelium and undergo hyperplasia over time.<sup>3</sup> To the time of writing, there are no reported cases in the literature of malignant transformation in the small bowel. Small bowel lesions typically present with abdominal pain and bleeding per rectum, but may be associated with a palpable abdominal mass, dyspepsia, intestinal obstruction, and perforation. Intussusception is also a known presentation, as in our patient's case, which proved to be a jejunum-jejunal intussusception. Our chosen initial operative approach



**FIG. 3.** (A) Low power view of giant polypoid gastric heterotopia in the jejunum. (B) High magnification shows gastric mucosa, including parietal cells.

was diagnostic laparoscopy. Once a dilated and thickened segment of proximal jejunum was identified during laparoscopy, we delivered the small bowel in order to palpate for intraluminal pathology. A 270-degree circumumbilical skin incision with vertical midline fascial incision allowed delivery of the entire small bowel for inspection and resection of the intraluminal mass. Tan and Bianchi first described this incision in 1986 for pyloromyotomy in hypertrophic pyloric stenosis.<sup>7</sup> We found that the incision provided excellent exposure and the additional advantages of a minimally invasive approach, including negligible scarring of the abdomen.

In conclusion, giant polypoid gastric heterotopia in the jejunum is uncommon. A laparoscopic-assisted approach with the Tan-Bianchi incision provides excellent exposure for management of patients with atypical intussusception.

### REFERENCES

1. Bhattacharya B, Jakate S, Saclarides T, Keshavarzian A. Gastric heterotopia presenting as a mass in jejunum. *Arch Pathol Lab Med* 2003;127:506–507.
2. Emamian SA, Shalaby-Rana E, Majd M. The spectrum of heterotopic gastric mucosa in children detected by Tc-99m pertechnetate scintigraphy. *Clin Nucl Med* 2001;26:529–535.
3. Jimenez JC, Sherif E, Steinmetz B, Romansky S, Weller M. Recurrent gastrointestinal tract bleeding secondary to jejunal gastric heterotopia. *J Pediatr Surg* 2005;40:1654–1657.
4. Lee SM, Mosenthal WT, Weismann RE, Hanover NH. Tumorous heterotopic gastric mucosa in the small intestine. *Arch Surg* 1970;100:619–622.
5. Nowak M, Deppisch L. Giant heterotopic gastric polyp in the jejunum. *Arch Pathol Lab Med* 1998;122:90–93.
6. Royle SG, Doig CM. Perforation of the jejunum secondary to a duplication cyst lined with ectopic gastric mucosa. *J Pediatr Surg* 1988;23:1025–1026.
7. Tan KC, Bianchi A. Circumumbilical incision for pyloromyotomy. *Br J Surg* 1986;73:399.

Address reprint requests to:

*Philip A. Omotosho, MD*

*Department of Surgery*

*Baystate Medical Center/Tufts University School of  
Medicine*

*759 Chestnut Street*

*Springfield, MA 01199*

*E-mail: philip.omotosho@bhs.org*