

Safety and efficacy of femoral-based hemodialysis access grafts

David B. Tashjian, MD,^a George S. Lipkowitz, MD,^a Robert L. Madden, MD,^a Jeffrey L. Kaufman, MD,^b Sang Won Rhee, MD,^b Joel Berman, MD,^b Marc Norris, MD,^b and Jane McCall, MS,^c *Springfield, Mass*

Objective: Arteriovenous fistulae traditionally have been placed in the upper extremity. Experience with groin hemodialysis access has been discouraging because of high infection rates and associated limb amputation. We reviewed our experience with angioaccess grafts in the groin to assess safety and viability in our hemodialysis patient population.

Methods: A retrospective review was performed of all groin hemodialysis access grafts placed at a single tertiary care center between June 1990 and February 1998. Demographics, complications, and subsequent treatment were recorded. Graft patency and infection rates were analyzed with life-table analysis.

Results: Data were collected on 73 graft insertions. A total of 52 episodes of thrombosis occurred in 26 grafts. Primary patency rate was 71% at 1 year. Secondary patency rate was 83% at 1 year. There was a 22% incidence rate of infection.

Conclusion: We conclude that the incidence rate of infection and thrombosis in our series of femoral-based hemodialysis grafts is comparable with rates reported in the literature for upper extremity polytetrafluoroethylene angioaccess grafts. Although not considered a first choice, femoral artery-based hemodialysis access is a viable option when arteriovenous fistulae in the upper extremity cannot be constructed. (*J Vasc Surg* 2002;35:691-3.)

During the past 30 years, dialysis access techniques have undergone extensive changes. Historically, arteriovenous fistulae created for dialysis access have commonly been placed in the upper extremity. In 1966, Brescia et al¹ introduced an internal arteriovenous fistula between the radial artery and the cephalic vein. Because some individuals are not candidates for native fistulae, expanded polytetrafluoroethylene grafts were developed and have been shown to be suitable substitutes.²⁻⁵ As techniques for hemodialysis access have evolved, different anatomic sites have been used for arteriovenous access. Used bilaterally, these include access sites with arterial inflow at the wrist, brachial-based located in the forearm, brachial-based in the upper arm, axillary-based in the upper arm or chest, and femoral-based in the groin.

Angioaccess in the groin has received little attention during the last two decades. Early experience with hemodialysis access in the groin was discouraging because of a high rate of infection and associated major limb amputation.^{6,7} Currently, groin access grafts are used for patients who have had failure of their upper extremity sites caused by repeated thrombosis, arterial steal syndrome, severe axillary or subclavian arterial disease, and venous obstruction. With the advent of polytetrafluoroethylene for prosthetic subcutaneous hemodialysis access and with improvements in surgical techniques and

dialysis care, the groin has again received attention as a valuable hemodialysis access site in our institution. We, therefore, reviewed our experience with angioaccess grafts in the groin to assess safety and viability in our hemodialysis patient population.

METHODS

Records from all groin hemodialysis access grafts placed between June 1990 and February 1998 were reviewed. All operations were performed at a single tertiary care center by one of six surgeons. The grafts were polytetrafluoroethylene loop grafts placed from the common or superficial femoral artery to the saphenous-common femoral vein junction or directly to the common femoral vein. Choice of specific polytetrafluoroethylene graft type was made by the individual surgeon and included grafts ranging from 6 mm to 8 mm in size made by manufacturers that included Goretex (Flagstaff, Ariz), Impra (Charlotte, NC), and Baxter (Irvine, Calif). Preoperative screening for occlusive disease in the vascular laboratory was performed at the surgeon's discretion. All complications and subsequent treatment, including thrombosis, infection, hematoma, psuedoaneurysm, steal, ischemia, seroma formation, and stenosis, were recorded.

Graft patency and infection rates were analyzed with life-table analysis and standards set by the Society for Vascular Surgery/North American Chapter and the International Society for Cardiovascular Surgery.⁸ As stated by the ad hoc committee, "the graft is considered to have 'primary' patency if it has had uninterrupted patency with either no procedure performed on it or a procedure, such as transluminal dilation or proximal or distal extension to the graft, to deal with disease progression in the adjacent native vessel."⁸ Secondary patency was defined as the total life of the graft from insertion until discontinuation or removal. Grafts that were functioning on last

From the Divisions of Transplant Surgery,^a Vascular Surgery,^b and Surgical Biostatistics,^c Baystate Medical Center, Tufts University School of Medicine.

Competition of interest: nil.

Reprint requests: David B. Tashjian, MD, Baystate Medical Center, Department of Surgery, 759 Chestnut St, Springfield, MA 01199 (e-mail: DBTASH@aol.com).

Copyright © 2002 by The Society for Vascular Surgery and The American Association for Vascular Surgery.

0741-5214/2002/\$35.00 + 0 24/1/121750

doi:10.1067/mva.2002.121750

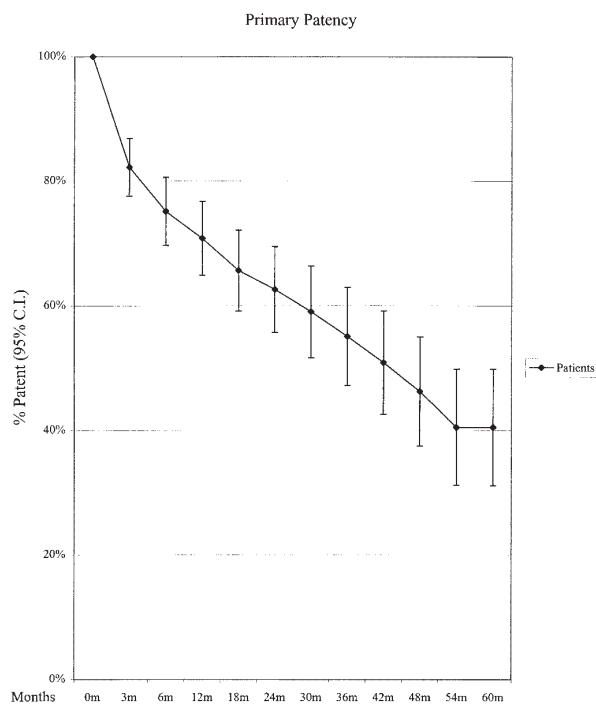


Fig 1. Life-table analysis results for primary patency rates. CI, Confidence interval.

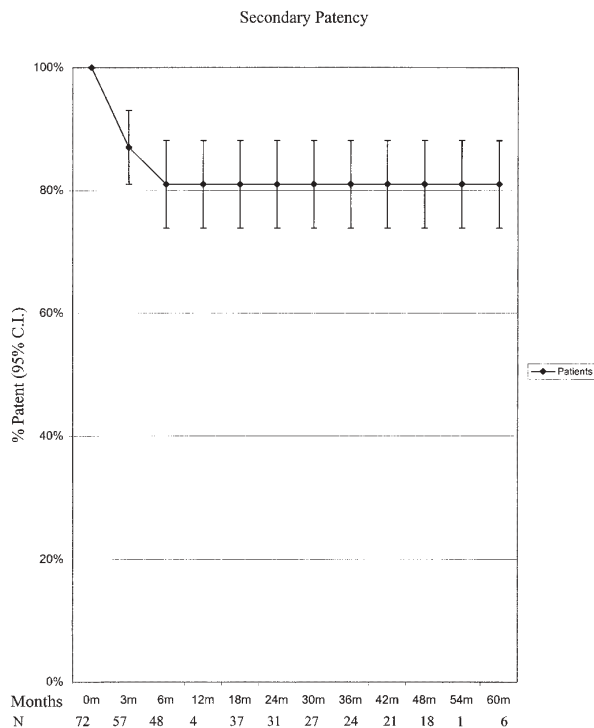


Fig 2. Life-table analysis results for secondary patency rates. CI, Confidence interval.

Patient demographics

| | No. of patients |
|-------------------------|-----------------|
| No. of patients | 73 |
| Mean age (years) | 62 |
| Sex (male:female ratio) | 32:41 |
| Race | |
| White | 41 |
| Black | 18 |
| Hispanic | 14 |
| Cause of renal failure | |
| Diabetes | 21 |
| Hypertension | 33 |
| Glomerulonephritis | 11 |
| Other | 8 |

follow-up examination but were discontinued for reasons other than failure were censored in the life-table analysis.

RESULTS

Data were collected on 73 graft insertions in 73 patients. Demographic data are shown in the Table. A total of 52 episodes of thrombosis occurred in 26 grafts. Sixty-four percent of these were treated with thrombectomy alone. Twenty-five percent of the thromboses were treated with thrombectomy and curettage. Standard embolectomy catheters were used for thrombectomy, and metal curetts were used to curett intimal hyperplasia inside the graft. None of the thrombosed grafts

were treated with thrombolysis. As shown in Fig 1, the primary patency rate was 71% at 1 year and 63% at 2 years. The secondary patency rate was 83% at 1 and 2 years (Fig 2).

Sixteen of 73 grafts (22%) had 17 episodes of infection, as identified with review of clinical charts. Four of the 17 episodes of infection were cellulitis and were treated with antibiotics alone. The other occurrences involved frank infection of the graft and required surgery for graft removal. All the infections occurred more than 1 month from the insertion date. Life-table analysis results revealed a 15% infection rate at 6 months, 22% at 1 year, and 24% at 2 and 3 years (Fig 3).

Complications of postcannulation hematomas, pseudoaneurysms, and graft stenosis were 4%, 8%, and 7%, respectively, during the follow-up period of the study. One of three hematomas required evacuation with placement of an interposition graft. Five of six grafts with pseudoaneurysms were treated with an interposition graft. Stenoses occurred in five grafts and were corrected either with radiographic angioplasty (n = 1), operative patch angioplasty (n = 2), or interposition grafting (n = 2).

One episode of an ipsilateral major amputation occurred. The patient had concomitant leg ischemia worsened by steal from the graft with no revision possible because of limited arterial inflow. The patient chose amputation of the extremity rather than discontinuation of dialysis. General acceptance of lower extremity grafts varied by patient. Some patients found their femoral

grafts uncomfortable and burdensome, but others preferred their femoral grafts to their previous upper extremity grafts.

DISCUSSION

With the life-span of patients with end-stage renal disease undergoing hemodialysis continuing to rise,⁹ it is the responsibility of the surgeon to create a strategy of dialysis access that maximizes the use of potential access sites. Ideally, any patient undergoing hemodialysis should receive an autogenous fistula that could be accessed throughout the patient's life. Unfortunately, autogenous access is often impossible because of the obliteration of important superficial veins by prior medical intervention. Therefore, many patients have a polytetrafluoroethylene graft placed in an upper extremity. It is our impression that, with modern surgical techniques, the groin deserves renewed attention as a useful site for hemodialysis access.

Khadra, Dwyer, and Thompson¹⁰ reported the only large series of groin grafts with which this series can be compared. They reviewed 74 polytetrafluoroethylene loop grafts placed in 61 patients. Twelve of 74 grafts (16%) had complications involving graft infection, with a graft salvage rate of more than 50% and no major limb amputation. The incidence rate of infection for our grafts was 22%, with no resultant amputation. This is comparable with reports of upper extremity polytetrafluoroethylene access infection rates that have been reported to range from 12% to 25%.²⁻⁵ Furthermore, infections are usually a result of graft cannulation and not a result of surgical creation.¹⁰ If careful consideration is given to sterile technique during cannulation, infection should not be a reason to abandon the groin as a dialysis access site.

With regards to graft thrombosis, our primary patency rate of 71% at 1 year compares favorably with a 1-year patency rate of 50% shown by Khadra, Dwyer, and Thompson.¹⁰ These primary patency rate results are similar to the 62% to 68% range reported for upper extremity graft primary patency rate.²⁻⁴ Secondary patency rates are also comparable. Multiple thrombectomies and graft revisions may be necessary, but long-term graft survival can be accomplished if the access is managed carefully and is not significantly worse than upper extremity access.

In conclusion, we believe that femoral artery-based hemodialysis access is a viable option on the basis of our data. The incidence rate of infection and thrombosis is comparable with upper extremity angioaccess, and the amputation rate is acceptably low. Though not commonly considered a first choice as a dialysis access site, the groin should be considered a safe and practical option when conventional arteriovenous fistulae in the upper extremity can no longer be constructed.

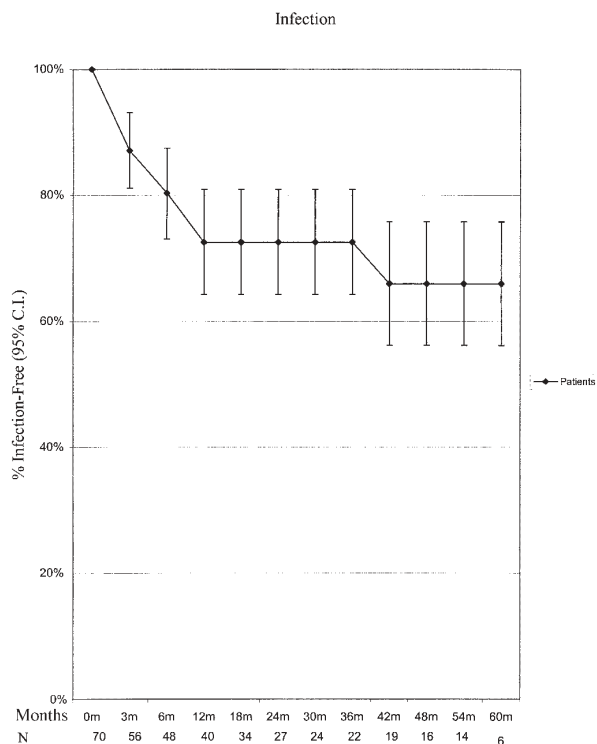


Fig 3. Life-table analysis results for infection rates. *CI*, Confidence interval.

REFERENCES

- Brescia MJ, Cimino JE, Appel K, et al. Chronic hemodialysis using venipuncture and surgically created arteriovenous fistula. *N Engl J Med* 1966;275:1089-92.
- Tellis VA, Kohlberg WI, Bhat DJ, et al. Expanded polytetrafluoroethylene graft fistula for chronic hemodialysis. *Ann Surg* 1979;189:101-5.
- Munda R, First MR, Alexander JW, et al. Polytetrafluoroethylene graft survival in hemodialysis. *JAMA* 1983;249:219-22.
- Palder S, Kirkman R, Whittemore A, et al. Vascular access for hemodialysis. *Ann Surg* 1985;202:235-9.
- Cinat ME, Hopkins J, Wilson SE. A prospective evaluation of PTFE graft patency and surveillance techniques in hemodialysis access. *Ann Vasc Surg* 1999;13:191-8.
- Mandel ST, McDougal EG. Popliteal artery to saphenous vein vascular access for hemodialysis. *Surg Gynecol Obstet* 1985;160:358-9.
- Connolly JE, Brownell DA, Levine EF, et al. Complications of renal dialysis access procedures. *Arch Surg* 1984;119:1325-8.
- Rutherford RB, Flanigan DP, Gupta SK, et al. Suggested standards for reports dealing with lower extremity ischemia. *J Vasc Surg* 1986; 4:80-94.
- Port FK, Orzol SM, Held PF, et al. Trends in treatment and survival for hemodialysis patients in the United States. *Am J Kidney Dis* 1998; 32:S86-7.
- Khadra M, Dwyer A, Thompson J. Advantages of polytetrafluoroethylene arteriovenous loops in the thigh for hemodialysis access. *Excerpta Medica* 1997;173:280-3.

Submitted Jul 3, 2001; accepted Oct 22, 2001.