

David B. Tashjian · Stanley H. Konefal

## Hypertrophic pyloric stenosis in utero

Accepted: 11 May 2001 / Published online: 5 June 2002  
© Springer-Verlag 2002

**Abstract** Hypertrophic pyloric stenosis (HPS) is the most common surgical condition producing vomiting in infants. It has been reported as early as the 1st week of life. We report an infant with HPS seen on prenatal ultrasound. Although infants with HPS usually present between 3 and 5 weeks of life, HPS must be considered as part of the differential diagnosis of newborns with non-bilious vomiting.

**Keywords** Pyloric stenosis · Non-bilious vomiting

### Introduction

Hypertrophic pyloric stenosis (HPS) is encountered frequently in pediatric surgery, occurring in about 1 in 300 live births. HPS is the most common surgical condition producing vomiting during infancy, with an age range of symptom onset of between 3 and 5 weeks [1]. The literature has identified patients diagnosed with HPS during the 1st week of life, and two who were 18 years of age [1–3]. We report an infant with prenatal ultrasonic (US) evidence of HPS.

### Case report

A 4,878-g male was delivered vaginally at 41 2/7 weeks with Apgar scores of 8 and 9. An US scan one day prior to delivery revealed a grossly distended fetal stomach and an identifiable duodenal cap (Fig. 1). Shortly after beginning feedings, the patient developed non-bilious projectile vomiting. An upper gastrointestinal (GI) contrast series revealed markedly delayed gastric emptying without definite evidence of anatomic obstruction (Fig. 2). He was taken to surgery on the 2nd day of life with a pre-operative diagnosis of partial duodenal obstruction. HPS was found, and a Ramstedt

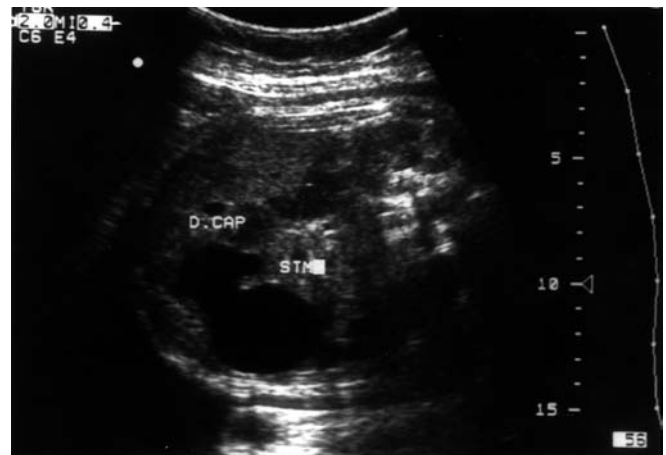
pyloromyotomy was performed. The patient was discharged tolerating full oral feedings.

### Discussion

As early as 1907, Dent reported a case of a 7-month-old fetus with HPS discovered at autopsy [4]. Zenn and Redo [5] described a patient with polyhydramnios on prenatal US, and non-bilious vomiting at birth. The child was operated upon on the 4th day of life. This represents a case of HPS in utero. Other reports of pyloric stenosis presenting during the 1st week of life exist [1–3, 6, 7].

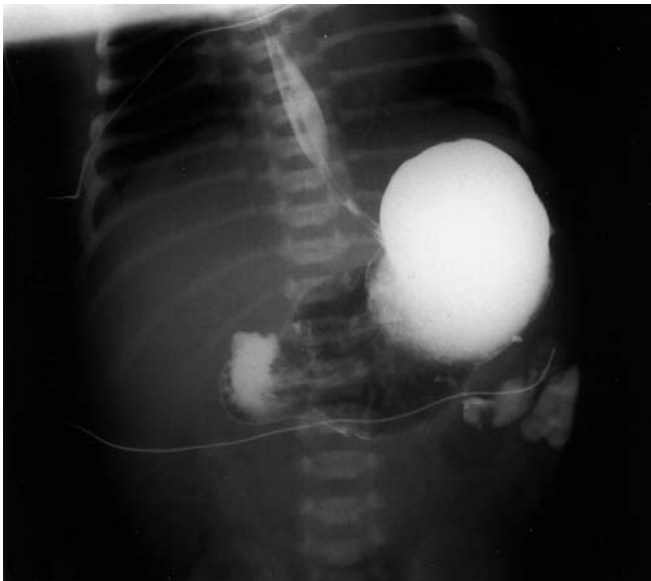With the improved diagnostic capability of US, infants with HPS are diagnosed earlier, which has led to a decreased emphasis on clinical skills to make the diagnosis. However, fewer electrolyte imbalances now exist in infants undergoing pyloromyotomy [8].

This case represents the earliest reported HPS repair (day 2 of life) in the surgical literature. A prenatal US scan demonstrating a dilated stomach, a visible



**Fig. 1.** Prenatal US scan showing dilated stomach (STM) and duodenal cap (D. CAP)

D.B. Tashjian (✉) · S.H. Konefal  
Division of Pediatric Surgery,  
Baystate Medical Center Children's Hospital,  
Tufts University School of Medicine,  
Springfield, MA 01199, U.S.A.



**Fig. 2.** Upper gastrointestinal series at 1.5 h revealing delayed gastric emptying and minimal filling of jejunum without evidence of anatomic obstruction

duodenal cap, and polyhydramnios can indicate HPS or another proximal GI obstruction. While HPS is traditionally considered an entity seen between 3 and 5

weeks of life, it clearly can present just after birth. In an infant with an inability to tolerate early feedings, non-bilious projectile vomiting, and the above-mentioned findings on prenatal US, HPS must be considered in the differential diagnosis.

---

## References

1. Pollock WF, Norris WJ, Gordon HE (1957) The management of hypertrophic pyloric stenosis at the Los Angeles Children's Hospital. *Am J Surg* 94: 335–349
2. Bell MJ (1968) Infantile pyloric stenosis: experience with 305 cases at Louisville Children's Hospital. *Surgery* 64: 983–989
3. Reyna TM, Otero C, Weir MR (1987) Epidemiological survey of 6 years federal health service experience of pyloric stenosis: case report of presentation in a 26-month male. *Clin Pediatr* 26: 412–414
4. Dent C (1907) Hypertrophic pyloric stenosis in infants. *Br Med J* 1: 627–628
5. Zenn MR, Redo SF (1993) Hypertrophic pyloric stenosis in the newborn. *J Pediatr Surg* 28: 1577–1578
6. Powell BW (1962) Early pyloric stenosis (correspondence). *Lancet* 2: 1326
7. Feldtman RW, Andrassy RJ, Larsen GL, et al (1976) Pyloric stenosis: a 13-year experience in operative management. *Am Surg* 42: 551–553
8. Chen EA, Luks FI, Gilchrist BF, et al (1996) Pyloric stenosis in the age of ultrasonography: fading skills, better patients? *J Pediatr Surg* 31: 829–830