

Laparoscopy for Treating a Small Bowel Obstruction Due to a Meckel's Diverticulum

David B. Tashjian, MD, Kevin P. Moriarty, MD

ABSTRACT

A Meckel's diverticulum is one cause of small bowel obstruction in the virgin abdomen. A 17-year-old female presented with a 24-hour history of lower abdominal pain and emesis. Radiological imaging studies revealed a high-grade partial small bowel obstruction. A diagnostic laparoscopy was performed revealing a bowel obstruction secondary to a Meckel's diverticulum. The diverticulum was resected using an endovascular GIA stapler. The patient was discharged on postoperative day 3, tolerating a regular diet. Laparoscopy is a useful diagnostic and therapeutic tool for a patient with a small bowel obstruction with an unclear etiology.

Key Words: Laparoscopy, Meckel's diverticulum.

INTRODUCTION

Beyond the newborn period, hernias, intussusception, congenital bands, appendicitis, and a Meckel's diverticulum are potential causes of a small bowel obstruction in the virgin abdomen. Meckel's diverticulum is the most frequent congenital anomaly of the gastrointestinal tract with an incidence of 2% in the general population.¹ Meckel's diverticulum can present as abdominal pain with an unclear cause, hematochezia, inflammation with or without perforation, intussusception, and a small bowel obstruction.^{2,3} In children with a small bowel obstruction, laparoscopy can be used for both diagnostic and therapeutic purposes. We present a case of a small bowel obstruction secondary to a Meckel's diverticulum, diagnosed and treated laparoscopically.

CASE REPORT

A 17-year-old female, with a reported history of irritable bowel syndrome and questionable Crohn's disease, presented with a 24-hour history of lower abdominal pain and emesis without flatus. Initial abdominal films revealed multiple air fluid levels (**Figure 1**). An upper gastrointestinal series was performed because of the question of Crohn's disease. It revealed poor filling of the terminal ileum consistent with a high-grade partial small bowel obstruction (**Figure 2**).

A diagnostic laparoscopy was performed. A 12-mm Hassan trocar was placed at the umbilicus via an open technique. Two additional 5-mm ports were placed, one in the right upper quadrant anterior axillary line, and one in the left lower quadrant anterior axillary line. A Meckel's diverticulum with a thick band from the tip of the diverticulum to the small bowel mesentery creating the obstruction was discovered. An obvious transition zone in the distal ileum existed at this point of internal small bowel herniation. The diverticulum was resected using an endovascular GIA stapler. The patient was discharged home on postoperative day 3, tolerating a regular diet.

DISCUSSION

The goals when managing a small bowel obstruction are

Division of Pediatric Surgery, Baystate Medical Center Children's Hospital, Tufts University School of Medicine, Springfield, Massachusetts, USA (all authors).

Address reprint requests to: Kevin P. Moriarty, MD, Pediatric Surgical Services, 125 Liberty St, Springfield, MA 01103, USA. Telephone: 413 734 3222, Fax: 413 731 8901, E-mail: kpmort@charter.net

© 2003 by JSLS, *Journal of the Society of Laparoendoscopic Surgeons*. Published by the Society of Laparoendoscopic Surgeons, Inc.

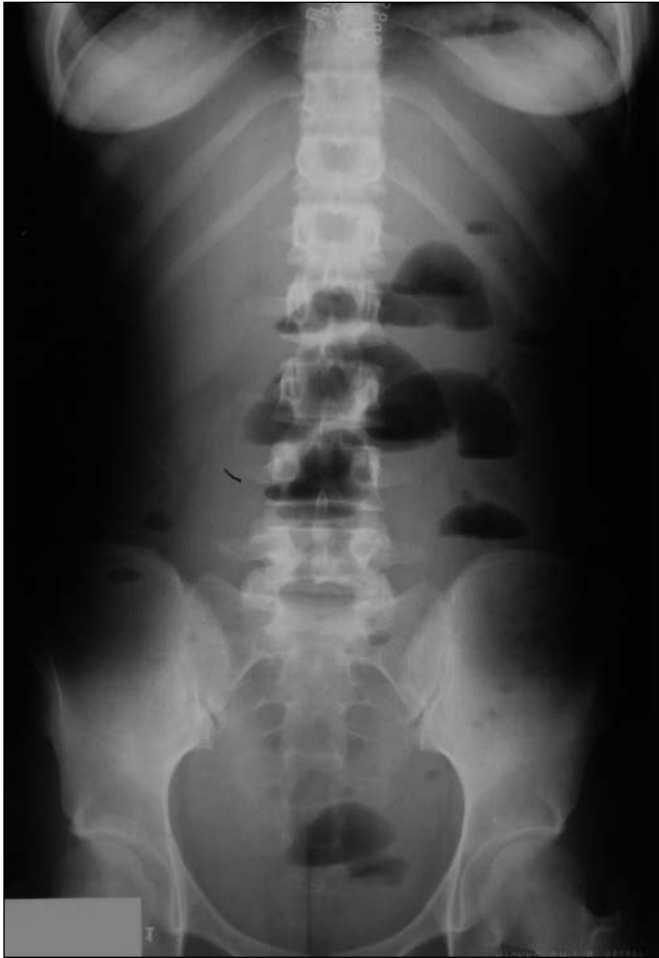

Figure 1. Plain abdominal film revealing multiple air fluid levels.

to identify the cause, relieve the obstruction, and ensure bowel viability.⁴ Often, a definitive preoperative cause cannot be determined. In patients whose obstruction is not relieved with nonoperative management, surgery is required to prevent bowel compromise. Laparoscopy provides a tool to diagnose the cause of the obstruction and often to relieve the obstruction without laparotomy.^{3,5}

Small bowel obstruction secondary to a Meckel's diverticulum most often results from intussusception or from herniation of bowel around a diverticular band.² Historically, laparotomy has been required to diagnose and treat these conditions. Attwood et al⁶ initially described resection of a Meckel's diverticulum using

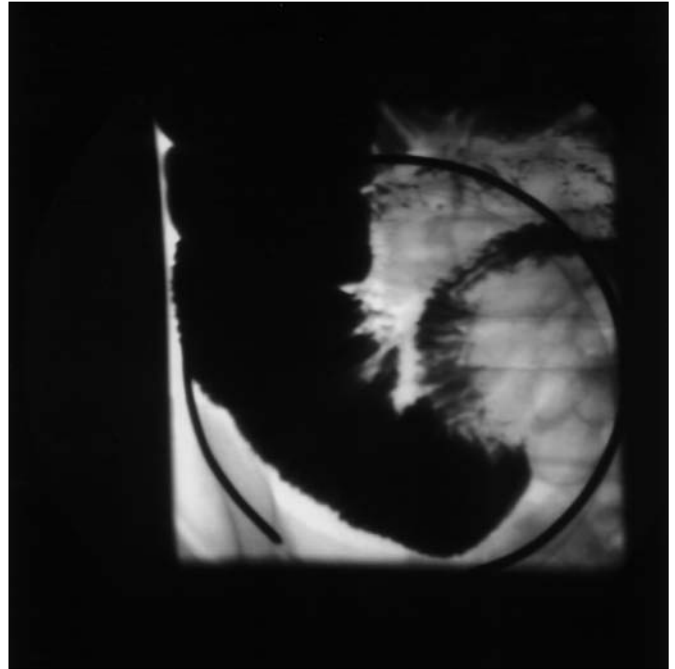


Figure 2. Upper gastrointestinal series with high-grade distal ileal obstruction.

laparoscopy. Subsequently, the use of laparoscopy has been reported in the pediatric population for resection of Meckel's diverticulum in cases of both bleeding and obstruction.^{2,3,7,8} In two of the cases,^{2,3} a diagnostic laparoscopy was performed to determine the cause of a bowel obstruction. A subsequent diverticulectomy was performed.

Laparoscopy was used for diagnostic and therapeutic purposes in the presented case. Laparoscopic access via an open technique helps minimize the risk of bowel perforation associated with a Veress technique. Laparoscopy also permits inspection of the remainder of the abdomen with reduced postoperative pain and potentially a decreased length of hospital stay. In cases of small bowel obstruction with an unclear cause, laparoscopy offers an excellent diagnostic modality. When a Meckel's diverticulum is found as the cause of obstruction, laparoscopy also provides a therapeutic modality, obviating the need for laparotomy.

References:

1. Oldham KT, Wesley JR. The pediatric abdomen. In:

Greenfield IJ, Mulholland MW, Oldham KT, Zelenock GB, eds. *Surgery: Scientific Principles and Practice*. Philadelphia: JB Lippincott Co; 1993:1832-1882.

2. Sanders LE. Laparoscopic treatment of Meckel's diverticulum. *Surg Endosc*. 1995;9:724-727.

3. Teitelbaum DH, Polley TZ, Obeid F. Laparoscopic diagnosis and excision of Meckel's diverticulum. *J Pediatr Surg*. 1994;29:495-497.

4. Ellis H. Acute intestinal obstruction. In: Schwartz SI, Ellis H, eds. *Maingot's Abdominal Operations*. Norwalk: Appleton & Lange; 1990:885-891.

5. Adams S, Wilson T, Brown AR. Laparoscopic management of acute small bowel obstruction. *Aust NZ J Surg*. 1993;63:39-41.

6. Attwood SEA, McGrath J, Hill ADK, et al. Laparoscopic approach to Meckel's diverticulectomy. *Br J Surg*. 1992;79:211.

7. Huang CS, Lin LH. Laparoscopic Meckel's diverticulectomy in infants: report of three cases. *J Pediatr Surg*. 1993;28:1486-1489.

9. Crosthwaite GL, Leather AJM. Laparoscopy: The ultimate diagnostic tool for a bleeding Meckel's diverticulum. *Aust NZ J Surg*. 1997;67:223-224.

Presented as a poster at the IPEG Meeting, Atlanta, Georgia, USA, March 28-30, 2000.