



# Outcomes after a Ladd procedure for intestinal malrotation with heterotaxia

David B. Tashjian<sup>a,\*</sup>, Bevin Weeks<sup>b,1</sup>, Martina Brueckner<sup>b</sup>, Robert J. Touloukian<sup>a</sup>

<sup>a</sup>Section of Pediatric Surgery, Yale University School of Medicine, New Haven, CT 06520, USA

<sup>b</sup>Section of Pediatric Cardiology, Yale University School of Medicine, New Haven, CT 06520, USA

## Index words:

Ladd procedure;  
Malrotation;  
Midgut volvulus

## Abstract

**Purpose:** Intestinal rotation abnormalities and complex congenital heart disease associated with heterotaxia coexist. Despite the risk for midgut volvulus, performing a Ladd procedure for asymptomatic malrotation with heterotaxia remains to be controversial because the presumed risk for postoperative complications is thought to exceed the benefits of the operation. The purpose of this study was to review the incidence of complications after a Ladd procedure in asymptomatic patients with heterotaxia to guide recommendations for this patient population.

**Methods:** The medical records of all patients with heterotaxia who underwent a Ladd procedure for asymptomatic malrotation between 1984 and 2004 were reviewed. Type of cardiac disease, postoperative complications, and survival were recorded.

**Results:** Twenty-two patients (9 boys and 13 girls) with heterotaxia underwent an elective Ladd procedure after their medical stabilization or surgical correction or palliation of their cardiac anomaly. Of these patients, 19 were younger than 1 month at the time of the operation. The remaining 3 patients underwent the operation when they were between 2 and 5 months old. Three of the 22 patients (14%) developed postoperative intestinal obstruction: lysis of adhesions was performed in 1 patient; another patient required a staged bowel resection for a closed loop obstruction; and yet another patient had recurrent midgut volvulus 4 years after an incomplete initial Ladd procedure. All patients survived the initial and secondary procedures. Four deaths, all more than 1 month after the surgery, occurred as sequelae of the underlying cardiac anomaly. Length of follow-up ranged from 1 to 17 years.

**Conclusions:** We report on a 14% risk of postoperative bowel obstruction after an elective Ladd procedure, as compared with a small but significant incidence of midgut volvulus in patients with malrotation in the setting of complex congenital heart disease. Our results support the conclusion that an elective Ladd procedure at a time of relative cardiac stability for selected patients with heterotaxia has an acceptably low morbidity and should be considered to prevent midgut volvulus.

© 2007 Elsevier Inc. All rights reserved.

Abnormalities in intestinal rotation and fixation are well known to occur in conjunction with disordered cardiac looping in heterotaxia because both processes depend on left-to-right positional information normally provided during the fourth week of embryonic development. A previous study from our institution demonstrated significant

\* Corresponding author. Pediatric Surgical Services, Springfield, MA 01103, USA. Tel.: +1 413 734 3222; fax: +1 413 731 8901.

E-mail address: dbtash@comcast.net (D.B. Tashjian).

<sup>1</sup> Bevin Weeks and David B. Tashjian contributed equally to this work.

morbidity for unoperated intestinal rotation and fixation abnormalities (IRFAs), showing a 14% incidence of IRFA complications requiring emergency surgery [1]. Heterotaxia represents the failure of the embryo to form appropriately asymmetrically along the left-to-right body axis and may include intraabdominal and intracardiac and vascular pathologies. Heterotaxia refers to any anatomical configuration that differs from complete situs solitus with levocardia and a D-cardiac loop (normal) and from situs inversus totalis with dextrocardia and an L-cardiac loop (Fig. 1). It represents a continuum of anatomical configurations that extend from isolated dextrocardia with abdominal situs solitus to the total absence of asymmetry along the left-to-right body axis that is seen in left isomerism (polysplenia) or right isomerism (asplenia) [1]. Congenital heart disease (CHD) is present in 90% or more of patients with heterotaxia, and its severity also represents a spectrum from isolated simple lesions, such as atrial septal defects, to more complex defects, including functional single ventricles with abnormalities of systemic and/or pulmonary venous return. Patients who typically present with the most severe forms of CHD are those with asplenia and right atrial isomerism. Intestinal malrotation is thought to occur in approximately 1 in 500 live births overall but is present in a much higher proportion of children and adults with heterotaxia [2]. The incidence of malrotation and other associated digestive tract disorders in these patients has been shown to be in the range of 40% to 90% [3,4].

Many patients with heterotaxia suffer from complex CHD, which in previous eras was often incompatible with long-term survival. However, ongoing advances in surgical interventions for congenital cardiac anomalies have resulted in the expectation of positive cardiovascular outcomes for patients such that their associated anomalies and medical

issues, including intestinal malrotation, have become more relevant concerns. Despite this, performing a Ladd procedure for asymptomatic malrotation with heterotaxia remains to be controversial because the presumed risk for postoperative complications is thought to exceed the benefits of the operation in the setting of significant CHD and suboptimal hemodynamics. Ruben et al [5] reported on 3 deaths in 7 neonates who underwent a Ladd procedure for an abdominal surgical emergency. Five of the 7 patients had a major CHD, which was responsible for 2 of the 3 deaths. In addition, in a previous report from this institution [1], midgut volvulus occurred in 4 patients with heterotaxia and unsuspected malrotation. This led to the recommendation for an elective Ladd procedure in asymptomatic patients with heterotaxia and IRFAs. A long-term study was then undertaken to review the incidence of complications after a Ladd procedure in asymptomatic patients with heterotaxia to guide surgical recommendations for this patient population.

## 1. Materials and methods

Patients who underwent a Ladd procedure for asymptomatic malrotation at Yale–New Haven Children’s Hospital between 1984 and 2004 were identified from the Yale University Pediatric Surgery database. These patients were cross-referenced with the Yale University Pediatric Cardiology database, and those with a cardiac and/or vascular anatomy consistent with a diagnosis of heterotaxia were included in the current study. The medical records of each of these patients were reviewed; type of cardiac disease, any complication after the Ladd procedure, and survival to the present time were recorded. The Yale University School of

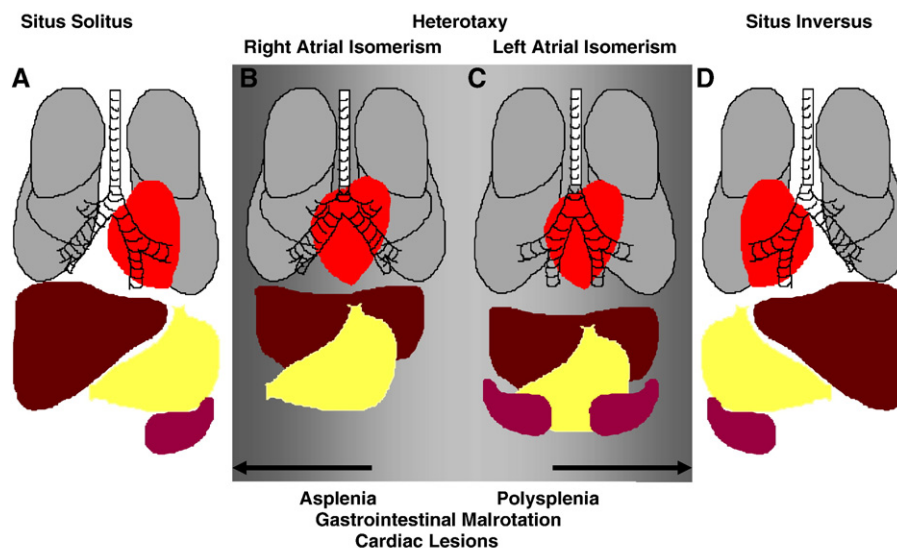


Fig. 1 Normal situs and situs abnormalities.

**Table 1** Cardiovascular anomalies in the 22 patients with heterotaxia

Cardiovascular anomaly	n
Dextrocardia	10
ASD	10
Sub-PS/PS/Atresia	9
Complete atrioventricular canal	8
D- or L-TGA	8
Single ventricle	6
VSD	7
DORV	5
TAPVR	5
Interrupted IVC	4
AV-VA discordance	3
Common atrium	1
LVOT/Aortic obstruction, including coarctation	1
Ebstein anomaly	1

ASD indicates atrial septal defect; PS, pulmonary stenosis; TGA, transposition of the great arteries; VSD, ventricular septal defect; DORV, double-outlet right ventricle; TAPVR, total anomalous pulmonary venous return; IVC, inferior vena cava; AV-VA, atrioventricular-ventriculoarterial; LVOT, left ventricular outflow tract.

Medicine Institutional Review Board granted approval for this retrospective record review.

## 2. Results

Twenty-two patients (9 boys and 13 girls) with heterotaxia, including 6 previously reported patients from our institution, underwent an elective Ladd procedure after their medical stabilization or surgical correction or palliation of their cardiac anomalies. The types of CHD present in these patients are detailed in Table 1. As anticipated in the setting of heterotaxia, there was a wide range of anomalies present, and most patients' anatomy was composed of more than one defect.

Four pediatric surgeons performed all the Ladd procedures in this series. Of the 22 patients, 19 were younger than 1 month at the time of the operation. The remaining 3 patients underwent the operation when they were between 2 and 5 months old. Nineteen patients underwent an elective procedure after an upper gastrointestinal series study that was obtained because of the presence of CHD suggestive of heterotaxia. Three patients were referred for diagnostic studies after presenting with persistent vomiting.

Long-term follow-up ranged from 1 to 17 years, with a mean of 9 years for the 22 patients in the series. Four deaths, all more than 1 month after the abdominal surgery, occurred as sequelae of the underlying cardiac anomaly. Three patients (14%) developed postoperative intestinal obstruction (Table 2), each requiring a second laparotomy between 3 weeks and 4 years after the Ladd procedure: 1 patient underwent lysis of adhesions; another patient required a staged bowel resection for a closed loop obstruction; and yet another patient had a recurrent midgut volvulus 4 years after the initial Ladd procedure requiring a second Ladd procedure. Previously undetected congenital bands were divided at the second procedure. There was no death caused by the initial or secondary laparotomy. None of these patients had required an antireflux procedure or gastrostomy.

## 3. Discussion

It has been reported that the mortality in children with malrotation and midgut volvulus without intestinal necrosis is typically a result of their other associated anomalies [6]. This is substantiated by the poor postoperative and long-term outcomes in patients with heterotaxia undergoing repair of their intestinal malrotation historically related to their cardiac disease rather than to the abdominal surgery itself. Nakada et al [3] reported on cardiac-related deaths in 4 of their 5 patients with heterotaxia between 3 months and 4 years old who underwent a Ladd procedure, with no immediate postoperative death. Only 1 of the 6 patients in their series identified with an abnormality of intestinal rotation who did not undergo surgical intervention survived for more than 3 months. Eight of the patients in that study died of cardiac insufficiency, whereas 1 patient died of hepatic failure. Despite the high mortality, the authors recommended evaluation and operation for associated digestive tract disorders when patients are in a stable condition.

Our findings in the present study reflect a far better outcome for patients with heterotaxia and malrotation who underwent a Ladd procedure after correction or palliation of the cardiac anomaly, indicating the importance of excellence in performing the heart operation. The 4 deaths in our patient population were a result of a severe underlying cardiac defect and were remote from the Ladd procedure.

Although the risk for postoperative bowel obstruction after a Ladd procedure does exist, the true incidence of

**Table 2** Patients with heterotaxia who developed complications after their Ladd procedure

Patient	Sex	Cardiac defects	Age at Ladd procedure	Postoperative complication	Time to reoperation
1	Female	Pulmonary atresia; VSD	3 wk	Bowel obstruction	25 d
2	Male	D-TGA; ASD/VSD; sub-PS	1 mo	Midgut volvulus	4 y
3	Female	Dextrocardia; DORV with L-TGA; CoA; HLHS	1 mo	Bowel obstruction	2.5 mo

CoA indicates coarctation of the aorta; HLHS, hypoplastic left heart syndrome.

midgut volvulus in patients with malrotation not undergoing a Ladd procedure is difficult to assess because the total population with asymptomatic malrotation cannot be accurately defined. Clearly, complications of abnormal intestinal fixation and rotation can occur at any age, and this possibility must be weighed against the risk for postoperative complications in patients with a very complex cardiac lesion when making recommendations regarding a Ladd procedure to those with asymptomatic malrotation and heterotaxia. In the original study from our institution, all of the 6 patients who underwent an elective Ladd procedure were alive and free of postoperative complications 6 months to 3 years after the surgery [1]. They remain free of adverse intraabdominal events to the present, although 1 of the 6 patients subsequently died of complications from his severe CHD when he was approximately 4 years old. Our incidence of postoperative bowel obstruction (14%) in the present study is higher than the 5% incidence of bowel obstruction that is often cited after any laparotomy but is within an accepted incidence for bowel obstruction after a Ladd procedure. In a recent study recommending observation only for atypical malrotation, 8 of 29 patients (28%) required an operation based on colicky abdominal pain, bilious emesis, and/or feeding intolerance [7].

The long-term outcomes of patients with heterotaxia and complex CHD are variable and constantly subject to change and anticipated improvement as medical therapeutics and surgical techniques for the management of complex CHD continue to evolve and improve. The cardiac lesions seen in the heterotaxia population are not universally lethal; in addition, although there may be mortality associated with these patients' CHD, it is not inevitable. However, it is well known that patients with a complex intracardiac anatomy, such as functional single ventricles, are at risk for adverse events, such as the development of impaired ventricular function and arrhythmias over time. Thus, if there is a role for an elective Ladd procedure in patients with heterotaxia and abnormalities of abdominal rotation and fixation, this procedure is best undertaken at times of relative cardiac stability even in the face of a slightly increased risk for postoperative obstruction rather than as a semiurgent or an emergent surgery when an individual patient's cardiac status may be relatively fragile.

None of the patients in the present study had required an antireflux procedure or gastrostomy subsequent to the Ladd

procedure. Although CHD with associated imbalances between systemic and pulmonary blood flow may lead to a child's inability to maintain adequate energy intake or to increased daily energy requirements, the diagnosis of heterotaxia itself should not be a risk factor for reflux or feeding issues and the need for additional abdominal procedures unrelated to the Ladd procedure would not be predicted for many patients.

Many Ladd procedures are now being performed via laparoscopy, which may further decrease the operative morbidity in patients with heterotaxia and decrease the incidence of postoperative bowel obstruction. Opponents of this approach argue that the adhesions formed from the laparotomy help prevent recurrent volvulus.

Given the potential for a catastrophic abdominal event resulting from uncorrected intestinal malrotation in the setting of complex CHD and the overall improved survival of patients with complex CHD, our results demonstrate a low incidence of complications after a Ladd procedure and suggest that an elective Ladd procedure for patients with heterotaxia and asymptomatic malrotation has an acceptably low morbidity. Most importantly, the Ladd procedure should be considered when symptoms of patients' heart disease are well controlled rather than delaying interventions until an emergent operation is required at a time when patients' hemodynamic status may be less favorable.

## References

- [1] Chang J, Brueckner M, Touloukian RJ. Intestinal rotation and fixation abnormalities in heterotaxia: early detection and management. *J Pediatr Surg* 1993;28:1281-5.
- [2] Strouse PJ. Disorders of intestinal rotation and fixation ("malrotation"). *Pediatr Radiol* 2004;34:837-51.
- [3] Nakada K, Kawaguchi F, Wakisaka M, et al. Digestive tract disorders associated with asplenia/polysplenia syndrome. *J Pediatr Surg* 1997; 32:91-4.
- [4] Ditchfield MR. Intestinal rotational abnormalities in polysplenia and asplenia syndromes. *Pediatr Radiol* 1998;28:303-6.
- [5] Ruben GD, Templeton Jr JM, Ziegler MM. Situs inversus: the complex inducing neonatal intestinal obstruction. *J Pediatr Surg* 1983;18:751-6.
- [6] Messineo A. Clinical factors affecting mortality in children with malrotation of the intestine. *J Pediatr Surg* 1992;27:1343-5.
- [7] Habib CM, Jackson RJ, Kokoska ER, et al. Atypical malrotation: is observation safe? Presented at the 36th annual meeting of the American Pediatric Surgical Association, Phoenix, AZ, May 1, 2005.