



# Orthopaedic Care for **KIDS**

VOLUME 11 ISSUE 11



## IN THIS ISSUE

New Surgical Tools for the Treatment of Hip Dysplasia

Hospital Employee Develops New Way to Anchor Prosthesis

“ACE” is a Minimally Invasive Surgical Procedure

## SAVE THE DATE!

**Twelfth Annual Bone & Joint Course** for Pediatricians and Family Physicians

**Thursday, June 12, 2008**  
**1:00 - 5:30 pm**  
**Lunch - Noon**

For registration or information or call Lori Lemon at 413.787.2027 or [llemon@shrinenet.org](mailto:llemon@shrinenet.org)

## TO REFER A PATIENT

For an appointment or to make a referral call 413.735.1234 or 800.322.5905

## **Surgical Dislocation of the Hip and the Periacetabular Osteotomy of Ganz:**

### **New Surgical Tools or the Treatment of Hip Dysplasia and Femoracetabular Impingement**

[Philip Mack, M.D., Staff Surgeon](#)

It is estimated that 250,000 total hip replacements are performed annually in the United States for end-stage arthritis of the hip. The vast majority of those total hip replacements are done for arthritis with its origin in childhood hip disorders such as Developmental Dysplasia of the Hip (DDH), Legg-Calvé-Perthes (LCP) and Slipped Capital Femoral Epiphysis (SCFE). These child hip disorders alter the shape of the femoral head or coverage of the acetabulum leading to altered mechanical forces that accelerate arthritis of the hip. Prior to 1975, these three hip disorders (DDH, LCP and SCFE) were felt to contribute to 59% of the end-stage arthritis. The remaining 31% were designated as having “intrinsic hip arthritis” with no obvious etiology to explain the destruction of the hip joint. In a landmark study in 1975, Stulberg et al. by closely examining radiographs and redefining DDH and subtle aspects of SCFE, reduced the “idiopathic” hip arthritis to less than 12%. Over the last decade, Professor Reinhold Ganz in Switzerland, using his technique of “safe” surgical dislocation and direct examination of hips in various stages of degeneration, has clarified our understanding of this last small group of “intrinsic hip arthritis.” This group shares subtle abnormalities in femoral head shape and acetabular fit that lead to his concept of “cam” and “pincer” femoral acetabular impingement.

Femoracetabular impingement occurs when a mismatch between the femoral head and the acetabulum leads to irregular pressure at the acetabular juncture, labral injuries and cartilage damage. There are two types described. “Cam impingement” occurs when a nonspherical femoral head attempts to rotate into the more spherical acetabulum. The aberrant portion of the femoral head and neck junction may be an enlarged osteochondral prominence or a subtle mismatch in radial circumferences between the femoral head and acetabulum. “Pincer impingement” occurs when the femoral neck hits the acetabular rim of a very deep acetabular socket. Cam and Pincer occur in combination or isolation. This simple, yet elegant model of hip impingement allows surgeons to analyze abnormal hip mechanics and tailor surgical treatment strategies to reduce or eliminate these mechanical hip problems that lead to progressive degeneration.

Patients with hip pathology related to impingement or persistent dysplasia may present with the insidious onset of minor hip or groin pain with sporting activities that may progress to severe pain limiting all activities. Sitting may aggravate the symptoms as the deformed femoral head is forced into the acetabulum. Physical exam reveals pain with flexion and attempted internal rotation of the hip—an exam that will mimic SCFE. In fact, a minor asymptomatic SCFE is one potential etiology of cam impingement. After the initial history and physical, radiographs ordered include an AP pelvis, faux profile views and laterals of the hip taken with 15 degrees of internal rotation. Additional information is obtained from MRI scans utilizing intra-articular gadolinium and, if needed, a 3-D CT scan in severe deformities. Each patient is assessed in our Clinical Outcomes Assessment Laboratory prior to surgery and will be analyzed at intervals post-operatively to monitor patient satisfaction and response to surgery.

Two very powerful tools developed by Dr. Ganz in Switzerland, the periacetabular osteotomy (PAO) for residual dysplasia and the safe surgical dislocation for treatment of femoral head and acetabular pathology, are now routinely performed at Shriners Hospital in Springfield.

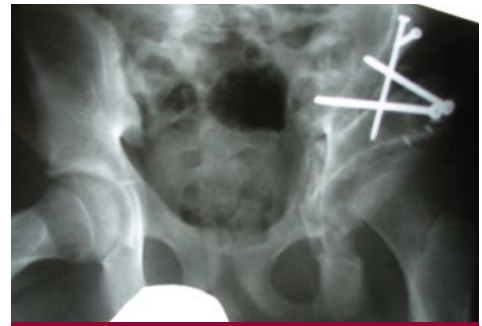The periacetabular osteotomy of Ganz (PAO) allows surgeons to correct residual acetabular dysplasia with extraordinary power and stability. Screw fixator allows immediate mobilization without the need for post-operative casting or bracing. By creating quadrangular cuts adjacent to the acetabulum, the complete acetabulum may be rotated in multiple planes to improve acetabular coverage and improve hip mechanics.

The second tool of the femoral head, surgical dislocation uses a digastric osteotomy of the greater trochanter and a surgical approach preserving femoral head blood supply supplied by the medial femoral circumflex artery. After anterior capsulotomy, the hip is dislocated allowing inspection and treatment of acetabular and labral pathology and reshaping of the femoral head and neck junction.

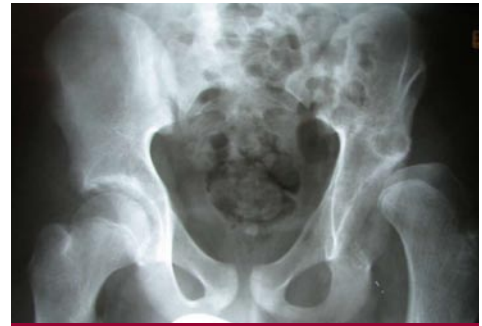Many patients with DDH, LCP and SCFE have mechanical abnormalities that may be addressed with these two techniques. DDH patients with severe residual acetabular dysplasia and subluxation are treated with the PAO. At times the PAO is combined with a proximal femoral osteotomy and capsulotomy to directly assess the relationship between the femoral head and acetabulum during flexion and internal rotation. A limited femoral head and neck osteochondroplasty can be performed if needed.

Legg-Calvé-Perthes is an idiopathic osteochondrosis of the proximal femoral epiphysis that leads to an enlarged and flattened femoral head. Residual acetabular dysplasia may also be seen. Ultimately, the majority of these patients will require a hip replacement by the age of 50 and some at a much younger age. The enlarged femoral head enters the acetabulum during flexion creating abnormal joint pressures and cartilage destruction. Surgically dislocating the femoral head allows the surgeon to trim away the impinging portion of the femoral head and treat the acetabular and labral damage.

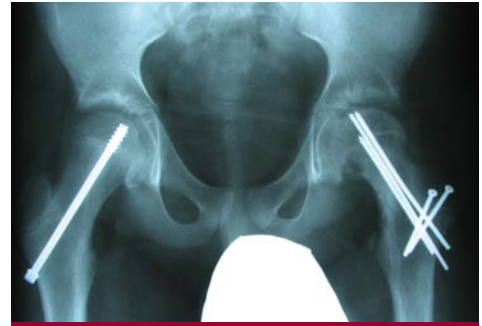The application of surgical dislocation of the femoral head to SCFE may revolutionize our approach to both chronic and acute SCFE. A patient presenting with an acute unstable slip treated with a gentle reduction and pinning has a 30-50% chance of developing avascular necrosis of the femoral head and subsequent severe arthritis. Most acute unstable SCFE are the sudden slippage of a chronic SCFE. The body has attempted to heal the chronic SCFE thus creating an enlarged callus that deforms the femoral neck. By reducing the acute slip across this enlarged bone, the blood vessels are stretched and AVN ensues. Surgical dislocation in the acute stage allows direct trimming of this hypertrophic bone, anatomic restoration of the femoral head atop the trimmed neck and stabilization with pins or screws. This technique appears very promising in reducing the overall incidence of AVN in this unstable SCFE population.



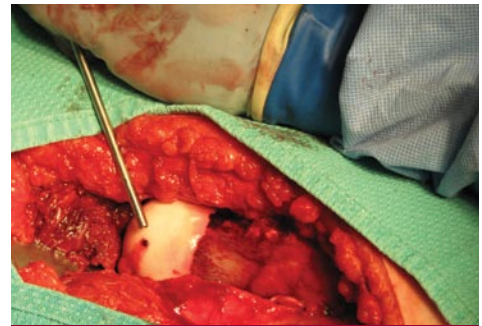
Dysplasia



Periacetabular Osteotomy (PAO)



SCFE



Femoral Head Bleeding SCFE

Applying these hip preserving techniques to our Shriners Hospital patient population offers each patient an opportunity to enter adulthood with the best possible mechanical environment for their native hip with hopes of postponing or preventing the need for hip replacement later in adulthood.

*In 2007, Dr. Mack spent six weeks studying Dr. Ganz's procedure at Inselspital Hospital in Bern, Switzerland.*



Philip Mack, M.D.

# Ipsilateral Scapular Cutaneous Anchor

Debra Latour, M.Ed., OTR/L

## INTRODUCTION

As an occupational therapist, my primary goals are to help clients develop skills to live as independently as possible and to help improve the quality of their lives. In an effort to achieve these goals for our upper limb deficient clients, I invented a new and improved way of harnessing a body-powered prosthesis called the Ipsilateral Scapular Cutaneous Anchor. The design eliminates the harnessing which is often a source of complaint and one reason why users reject prostheses.

Traditionally, a body-powered prosthesis is activated by a figure-of-eight or a figure-of-nine harness system, using the contra-lateral shoulder as the power source. Many users of this system complain of discomfort from the harness rubbing on the skin especially in the axilla and at the O-ring, asymmetry of the shoulders, pain in the contra-lateral shoulder area, difficulty while performing bilateral tasks, and diminished cosmesis.

The Ipsilateral Scapular Cutaneous Anchor (the "Anchor") system derives its primary source of control from the ipsilateral scapula. The "Anchor" requires a tighter fitting socket due to the elimination of the suspension support from the harness. The cable is attached to a plastic patch in the center of which is a metal button. The patch is adhered to the skin at the scapula. The terminal device is then operated by abducting/protracting the shoulder on the same side as the residual short limb. Because the harness is eliminated, the benefits of the system include increased comfort, improved cosmesis and decreased impingement at the axilla. Other benefits include more symmetrical bilateral muscle development, decreased repetitive motion in the contra-lateral shoulder and increased function particularly during bilateral upper extremity tasks. A Record of Medical Invention has been filed by Shriners Hospitals for Children and this technology is in patent-pending status with the United States Patent Office.

The Anchor has been used in treatment since August 2006. Pediatric patients may derive benefit and improved function of their unilateral upper extremity prosthesis with the use of this device.

## METHOD

**Subjects:** To date, 20 subjects; ages 6-20 years with congenital or acquired unilateral trans-radial deficiency most whom were active users of a body-powered prosthesis, with either a voluntary opening or voluntary closing terminal device have chosen to use the Anchor.

**Apparatus:** The anchor system attached to the scapula ipsilateral to the limb deficiency.

**Procedures:** Each patient is evaluated in a multi-disciplinary clinic. A screening tool and interview are used to identify suitable candidates. Once prescribed by the physician, the prosthetist fabricates a new tighter fitting forearm socket. The prosthetist and the occupational therapist fit the patient with the Anchor. Prosthetic training is provided which includes application, skin hygiene, use and care of the Anchor. Baseline testing is completed which includes the PSI and the U-BET, as well as, clinical observations using both the traditionally-harnessed prosthesis and the new Anchor activated prosthesis. The patient uses the new prosthesis for three months and then returns for re-testing utilizing the same tools.

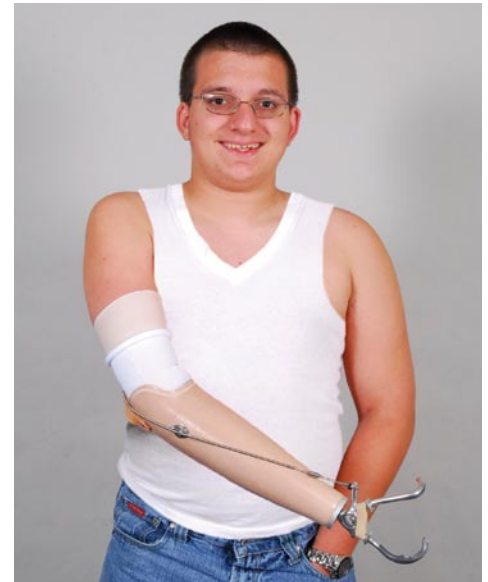**Data Analyses:** Data is currently being collected for a retrospective case study and will include functional abilities and quality of life measures.

## RESULTS

Initial observations have been reported to include ease in application, continued success with prosthetic use, increased use, improved cosmesis and patient satisfaction. Results are anticipated for the summer of 2008.

## DISCUSSION

The Anchor is simple in design and the parts are durable, easily available and



First patient fitted with the "Anchor".

affordable. The potential benefits of this system may result in increased prosthetic wear and use (tolerance, frequency and spontaneity) as it allows for improved comfort, cosmesis and ease of use during functional activity, particularly during bilateral tasks. Implications for use include the possibility of a hybrid-type of power system for individuals with trans-humeral deficiency. The Anchor might also be utilized to 'dynamize' an elbow, wrist or hand orthosis to increase function among individuals with spinal cord, brachial plexus or hemiplegic involvement. Future studies hope to include members of these populations.

## CONCLUSION

This device enables individuals with upper extremity limb deficiency to achieve greater levels of functional independence and improved quality of life.

## REFERENCES

Available upon request.



Debra Latour, M.Ed., OTR/L

# “ACE” is a Minimally Invasive Surgical Procedure to Help in the Management of Fecal Incontinence

Kevin P. Moriarty, M.D., FAAP, FACS, Consulting Staff Pediatric Surgeon

Chronic constipation and fecal incontinence present multiple psychological issues for children and their families. Spina bifida, anorectal malformations, Hirschsprung’s disease, trauma resulting in spinal injury, and idiopathic constipation can lead to encopresis. Often children require aggressive bowel management including enemas to keep them clean and out of diapers. In 1990 a surgical procedure to administer enemas antigrade through the appendix was described by Malone. The procedure is often referred to as a MACE (Malone **antigrade contince enema**).

The concept of the procedure is that a catheter is placed surgically into the colon and an enema is given via the catheter into the colon as the child sits on the commode to evacuate their bowels thus, rendering the child out of diapers for the day. Often the patient can administer the “ACE” themselves giving them independence unlike with a conventional enema.

To be a candidate for the procedure the child needs a work up which may include a colonoscopy with rectal biopsies, abdominal radiographs, sacral films, spinal MRI, contrast enema, sitz marker study, anorectal manometry, as well as defacography.

The best results are achieved with a highly motivated patient and parents.

Since 1998 we have performed 22 “ACE” procedures in 17 boys and 5 girls. The age range was 2-20 years with a mean age of 11. The indications for the operation were as follows: spina bifida 9, idiopathic 6, anorectal malformation (ARM) 4, mitochondrial disorder 2, ARM and Hirschsprung’s disease 1.

An appendicostomy was created in 18 patients, 2 had a cecostomy and 2 had the irrigation catheter placed in the sigmoid. The majority of the procedures were performed laparoscopically (18) and 3 of the 4 open operations were combined with another open procedure.

We had no major complications but a number of minor complications including: leaking, granulation tissue, stenosis, infection, mucosal prolapse, tube dislodgement and poor compliance.

The majority of patients and families are satisfied with the procedure.

In conclusion laparoscopy offers a minimally invasive approach to the ACE. Patient selection is critical to the success of the procedure.

*Presented at IPEG 2000: The IX<sup>th</sup> International Congress for Endosurgery in Children, Atlanta, Georgia, March 2000.*

Kevin P. Moriarty, M.D.



## SPECIALTY CLINICS

Each weekday children are seen in specialty clinics in the hospital’s Outpatient Department. Specialty clinics are held weekly, bi-weekly or monthly:

- Club Foot
- Developmental Dysplasia of the Hip and Other Hip Disorders
- Legg-Calvé-Perthes Disease
- Congenital and Acquired Limb Deficiencies
- Scoliosis and Other Spine Deformities
- Hand Deformities
- Shoulder Deformities
- Osteogenesis Imperfecta
- Juvenile Rheumatoid Arthritis
- Chest Wall Deformities
- Neuromuscular Disorders including Cerebral Palsy
- Myelodysplasia (Spina Bifida)
- Genetic Counseling for Orthopaedic Conditions
- Metabolic Bone Disease
- Cleft Lip and Palate

For complete abstracts and references, contact: JoAnn Santana-Bates, Executive Assistant to the Chief of Staff, tel: 413.787.2058 or [jsantana@shrinersnet.org](mailto:jsantana@shrinersnet.org)

Editor: Bernadette A. White, Director of Public Relations & Marketing, tel: 413.735.1291 or [bwhite@shrinersnet.org](mailto:bwhite@shrinersnet.org)

**516 Carew Street  
Springfield, MA 01104-2396  
TEL: 413.787.2000  
800.322.5905  
[www.shrinershospitals.org](http://www.shrinershospitals.org)**

## SHRINERS HOSPITALS FOR CHILDREN

Shriners Hospitals for Children is a one-of-a-kind international health care system of 22 hospitals dedicated to improving the lives of children by providing specialty pediatric care, innovative research and outstanding teaching programs. Children up to age 18 with orthopaedic conditions, burns, spinal cord injuries and cleft lip and palate are eligible for care and receive all services in a family centered environment at no charge regardless of financial need.

In Springfield, the medical team provides treatment for the most commonly seen to those rarely seen orthopaedic conditions on a daily basis. This team is comprised of board certified orthopaedic surgeons fellowship trained in pediatric orthopaedics, a pediatrician/pediatric rheumatologist, orthopaedic and plastic surgeons, physician extenders and 90 consulting physicians and surgeons.

Shriners Hospital in Springfield maintains teaching affiliations with Boston University School of Medicine and Albany Medical College. Additionally, the hospital provides training to undergraduate and graduate students in the fields of nursing, occupational therapy, physical therapy, orthotics, prosthetics, motion analysis, child life and social services.