

Feasibility of Thoracoscopic U-Clip Esophageal Anastomosis: An Alternative for Esophageal Atresia Reconstruction

By Michael V. Tirabassi, Gregory T. Banever, Kevin P. Moriarty, Stanley Konefal, Edward Reiter, and Richard Wait
Springfield, Massachusetts

Background: The authors propose that U-Clips can significantly decrease the technical difficulty of performing thoracoscopic esophageal reconstruction, thus, reducing operating time, the incidence of postoperative leak, and stricture rate.

Methods: After obtaining Institutional Animal Care and Use Committee approval, 3 4-kg female piglets underwent complete thoracoscopic esophageal transections. The esophagus was reconstructed thoracoscopically using S50 and S60 U-Clips over an 8F transanastomotic tube. Esophagrams were performed on postoperative day (POD) 7, 21, 44, and 77.

Results: Mean operating time was 57 minutes (45 to 75 min). Two of 3 piglets had no evidence of leak on POD 7 esopha-

grams. One animal had a small leak that resolved spontaneously on antibiotics. All 3 piglets tolerated a formula diet orally by POD 8. Over a 77-day survival period all 3 piglets had steady weight gain on an oral diet.

Conclusions: U-Clips are a feasible alternative to sutures for esophageal reconstruction in thoracoscopic surgery. Further study is warranted to investigate the full potential of U-Clips in minimally invasive pediatric surgery.

J Pediatr Surg 39:851-854. © 2004 Elsevier Inc. All rights reserved.

INDEX WORDS: Esophageal atresia, U-Clips, tracheoesophageal fistula, piglet, animal model.

ESOPHAGEAL ATRESIA repair is one of the most technically demanding thoracoscopic procedures performed in a newborn. With the introduction of new technology that decreases the technical difficulty of esophageal reconstruction, we expect that thoracoscopic esophageal anastomosis will be performed safely without significant postoperative stricture formation.

Development of an animal model that can mimic a human newborn infant with an esophageal reconstruction will allow testing of new technologies. The animal model should be both physically and physiologically similar to a human infant. Nine-day-old female swine will be selected as the animal model. Their initial starting weight is about 4 kg. In addition, they have the potential for a 10-fold increase in weight during the first 2 to 3 months of life.

Coalescent Surgical (Sunnyvale, CA) produces a novel suture assistance product called U-clips. These nitinol clips are metallic sutures. They are placed using a needle just like any other suture, but they “tie” themselves (Fig 1). They are small, delicate, and have been used with good success in both open and thoracoscopic cardiothoracic bypass surgeries. These clips have been shown to help increase anastomosis patency in the vascular system.^{1,2}

This study was designed to examine the utility of the U-Clip in esophageal reconstruction in a newborn piglet model.

MATERIALS AND METHODS

Nine-day-old female piglets were used as the animal model (about 4 kg). Before the survival experiments, the procedure was performed on

3 nonsurviving piglets of comparable size by the operating surgeon in an attempt to minimize technical error confounding the stricture formation in the survival piglets.

Anesthesia was induced with Isoflurane. Intravenous access was established either via auricular vein catheterization or cutdown catheterization of the external jugular vein with a size-appropriate catheter. The piglets were further sedated with midazolam, 0.5 mg/kg intravenously, and then paralyzed with pancuronium bromide, 0.12 mg/kg intravenously. A perioperative dose of cefazolin (20 mg/kg) was given intramuscularly before thoracoscopy. General endotracheal tube anesthesia was maintained with inhaled isoflurane titrated to effect and boluses of Fentanyl, 25 to 50 μ g/kg intravenously. A warmed operating table and intravenous fluids were utilized to minimize hypothermia during the procedure. The animal was placed in the prone position. Piglets were prepped and draped in a sterile manner with Duraprep.

Right thoracoscopy was performed using a 4-port technique (Fig 2). The esophagus then was completely transected sharply after being dissected free of both branches of the vagus nerve. After this, the esophagus was reconstructed using 8 S50 or S60 U-clips over an 8F transanastomotic tube. The port sites were closed in 2 layers with Dexon and Nylon. A 10F chest tube was inserted through the most inferior 3-mm port site and secured to a Heimlich valve on the second and third survival piglets. This was secured both with sutures and Vet Wrap. The

From the Division of Pediatric Surgery, Baystate Medical Center Children's Hospital, Tufts University School of Medicine, UMASS Baystate Medical Center Biosciences Initiative, Springfield, MA.

Presented at the 55th Annual Meeting of the Section on Surgery of the American Academy of Pediatrics, New Orleans, Louisiana, October 31-November 2, 2003.

Address reprint requests to Kevin P. Moriarty, MD, Pediatric Surgical Services, 125 Liberty St, Springfield, MA 01103.

© 2004 Elsevier Inc. All rights reserved.

0022-3468/04/3906-0014\$30.00/0

doi:10.1016/j.jpedsurg.2004.02.023

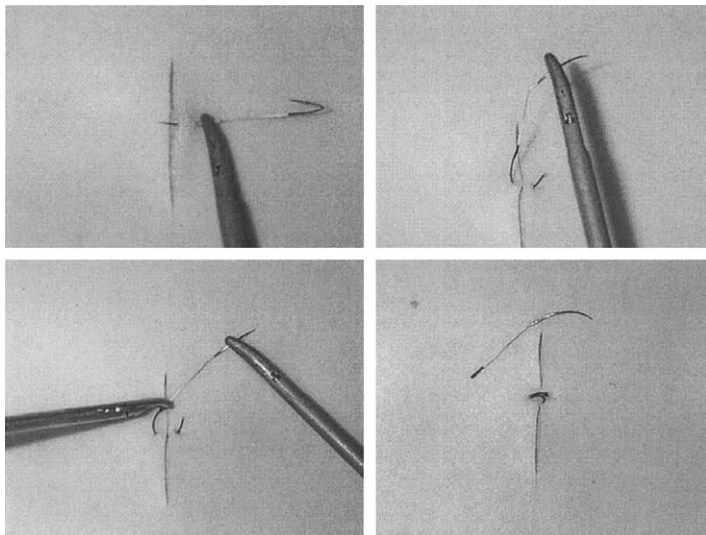


Fig 1. The U-Clip is a self-closing nitinol clip. The clips are placed in a similar manner to conventional suture. Once in place, the clip is released from the suture and needle. Upon release, the "memory" of the nitinol closes the clip with consistent strength and size. Panel A shows the U-Clip being placed in the same manner as suture with a 3.3-mm laparoscopic needle driver. In Panel B, the needle is pulled through and elevated approximating the tissue in the "U" of the Clip. In Panel C, the clip is about to be fired by compression of the release mechanism with the instrument on the left. Panel D shows the fired U-Clip closed and in place.

operating time, from incision until closure, was recorded. At the end of the procedure, a Stam gastrostomy tube was placed for postoperative feedings in the usual manner, and then the piglets were extubated and awakened from anesthesia. At least 30 minutes before awakening, a 25 $\mu\text{g/h}$ fentanyl patch was sutured in place on the back of the piglets' neck, and an intramuscular dose of flunixin (2.2 mg/kg) was administered. Postoperatively, piglets were observed closely and vital signs checked every 15 to 30 minutes until stable. The fentanyl patches were left in place for 72 hours. The flunixin was dosed every 12 hours for the first 48 hours postoperatively. D5/LR was given postoperatively until tube feedings were begun. Tube feedings were initiated 12 hours postoperatively with Grade A Ultra 24% Nursing formula. This was given at a goal of 96 mL/kg/d divided into 6 to 8 boluses daily. Tube feedings were continued until after the postoperative day (POD) 7 esophagram showed continuity through the Anastomosis into the stomach. After POD 7, piglets were fed formula ad libitum. The piglets were weaned to a grain diet by POD 14.

The piglets were kept alive for a total of 77 days postoperatively. They were weighed at least biweekly. The piglets were anesthetized for noninvasive studies on POD 7, 21, 44, and 77. The esophageal anastomosis was inspected by esophagoscopy on POD 21 and 44. Esophagrams were performed on POD 7, 21, 44, and 77 to follow the growth of the esophagus and the anastomosis diameter. Both posteroanterior and lateral chest x-rays were obtained, and the diameters were

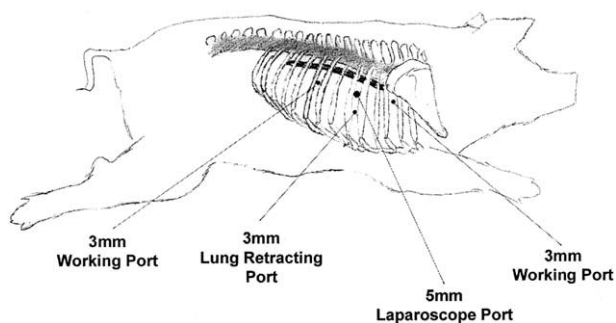


Fig 2. This sketch illustrates the port positions used during this study. At the start of the procedure, the piglet was placed in the prone position. Five-millimeter 30° and 45° laparoscopes were used for visualization. A 3-mm steel suction cannula was used via the lung retracting port to aid exposure with both retraction and suctioning when appropriate.

averaged. Anastomosis measurements were compared with the anastomosis of the distal normal-appearing esophagus.

RESULTS

Thoracoscopic esophageal transections and reconstructions with U-Clips were performed successfully. The operating times for the 3 survival piglets were 75 minutes, 50 minutes, and 45 minutes. The mean operating time was 56.7 minutes with a standard deviation of 16 minutes. All 3 piglets recovered from anesthesia without incident. Tube feedings were tolerated well.

During the first postoperative week, the piglets had a mean weight gain of only 0.03 kg. However, once the piglets were on an oral diet, they all gained weight (Fig 3). The average daily weight gain during the study period was 410 g/d with a standard deviation of 50 g. The mean weight gain for the entire study period was 31.55 kg with a standard deviation of 3.9 kg.

On the POD 7 esophagram, piglet A had a contained leak at the anastomosis. This was treated successfully with broad-spectrum antibiotics (Penicillin G, 40,000 IU/kg and Baytril, 2.5 mg/kg). Piglets B and C had no evidence of leak. The U-clips were visible on all 3 piglets. All 3 piglets were begun on an oral diet after the esophagrams were completed. The average anastomosis diameter was 5.16 mm with a standard deviation of 1.0 mm. The mean esophagus diameter was 8.33 mm with a standard deviation of 2.4 mm (Table 1).

On the POD 21 esophagram piglet A's leak was significantly improved. The other 2 piglets remained with no evidence of anastomotic leak. The nitinol U-Clips were no longer visible on any of the films after POD 7. After the second week postoperatively, the piglets were all tolerating a solid grain diet. Although the esophageal diameters were observed to increase, the anastomosis did not increase at the same rate. The mean esophagus diameter was 9.1 mm with a standard deviation of 2.4 mm.

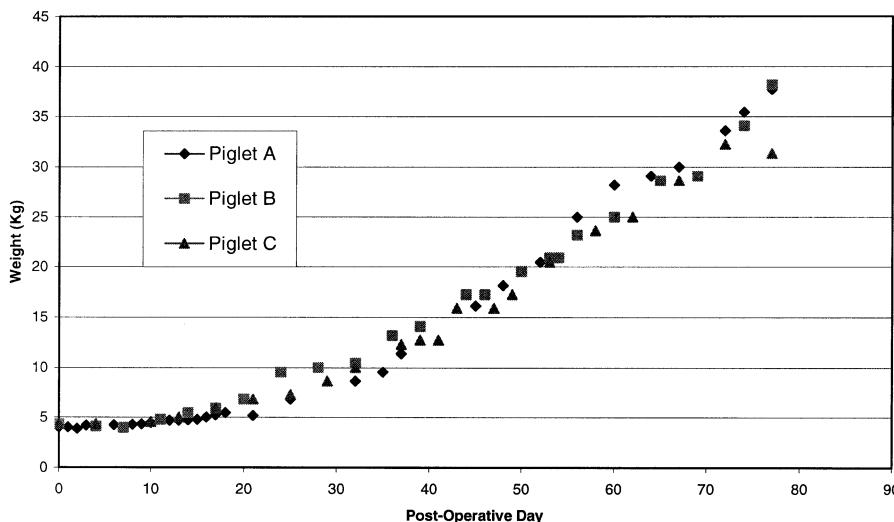


Fig 3. All 3 piglets did not have significant weight gain on gastrostomy tube feeding. After initiation of oral feeding, the piglets had progressive weight gain.

tion of 1.1 mm. The mean anastomosis diameter was 4.4 mm with a standard deviation of 3.7 mm. On the esophagoscopies, the anastomoses were identified. There was a small exudate covered region of Piglet A’s anastomosis, presumably the site of the healing leak. The other 2 anastomoses had no abnormalities.

On the POD 44 esophagrams, there were no leaks evident. The mean anastomosis diameter was 4.5 mm with a standard deviation of 0.5 mm. The mean esophageal diameter had increased to 13.1 mm with a standard deviation of 2 mm. On esophagoscopy of the 3 piglets, there were no abnormalities.

On the POD 77 esophagrams, all 3 anastomoses were intact (Fig 4). The mean anastomosis diameter was 4.6 mm with a standard deviation of 1.3 mm. The mean esophageal diameter was 15.2 mm with a standard deviation of 3.4 mm.

On necropsy, piglet A had scar formation at the anastomoses consistent with a healed leak. Piglets B and C had only normal postoperative adhesions on necropsy. All 3 anastomoses were identified and dissected grossly. U-Clips were not present in any of the anastomoses.

DISCUSSION

Esophageal atresia is a congenital disorder that traditionally requires a thoracotomy within the first few days of life for repair. With advances in thoracoscopy, there is potential to dramatically improve the care of children

that require thoracic surgery.³⁻⁵ Thoroscopic esophageal atresia reconstruction has been performed. Two case series of 8 patients each reported strictures requiring esophageal dilations in 50% of their patients.^{6,7} Operating times have been reported to range from 50 to 250 minutes with one study reporting a mean operating time of 138 minutes.⁷ Robotic-assisted reconstruction has been attempted in young piglets but was not superior to traditional thoracoscopy in a nonsurvival model.⁸ Because of these mixed results, the thoroscopic approach has been criticized and has not been accepted widely as appropriate treatment. Reconstructing the esophagus in a newborn is a complex procedure involving precise placement and tying of sutures not well suited to thoracoscopy. It has been previously suggested that technical error has contributed to the high postoperative stricture rates.⁷ We hypothesized that with the use of suture-assistance technology, we can decrease the technical difficulty of performing a thoroscopic esophageal anastomosis, thus, improving the short- and long-term outcome of infants with esophageal atresia by decreasing the number of complications caused by technical error.

One of the goals of this study was to establish an animal model that can measure the postoperative stricture rate of an esophageal atresia reconstruction so that the feasibility of new technologies could be evaluated. In this study, we proposed the use of female piglets that are about 4 Kg in weight. Smaller animals have been used in the past such as rats, but even a very large rat does not simulate the size or physiology of a human infant.⁹ The esophagus was transected completely, and then the esophagus was reconstructed thoracoscopically over an 8F transanastomotic tube with U-Clips. For the purpose of these initial studies, the anastomoses were created without tension. However, future studies with removal of progressively increasing lengths of esophagus could de-

Table 1. Postoperative Esophagrams

	Mean Esophagus Diameter (mm)	Mean Anastomosis Diameter (mm)	Mean Weight Gain (kg)
POD 7	8.33 (5.89-10.8)	5.16 (4.42-6.36)	0.03 (-0.36-0.23)
POD 21	9.1 (7.9-9.9)	4.44 (2.1-8.7)	2.06 (1.18-2.50)
POD 44	13 (11.4-15.3)	4.46 (3.9-5)	12.23 (11.59-12.95)
POD 77	15.2 (11.4-17.8)	4.47 (3-5.5)	31.55 (27.05-33.86)

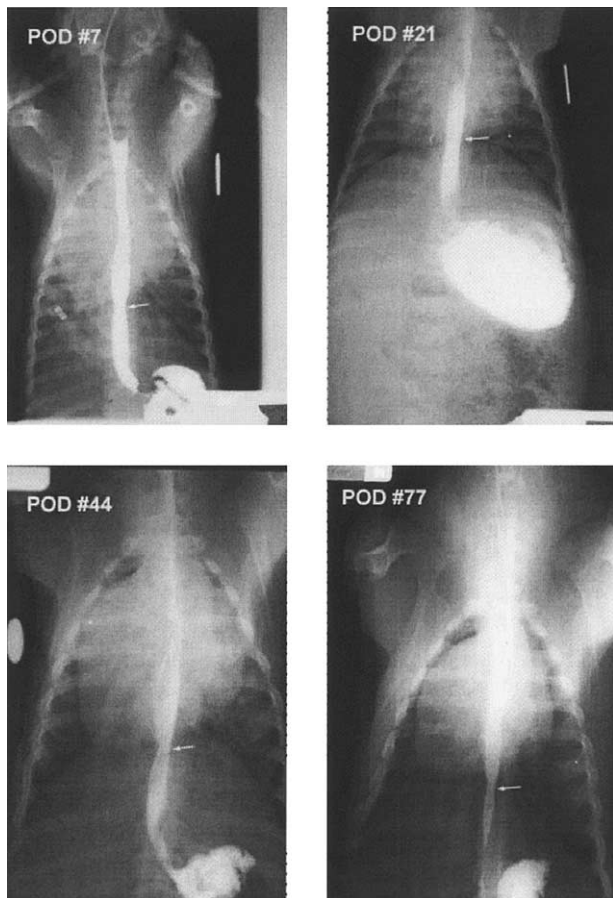


Fig 4. This is a representative esophagram series from piglet B. Arrows denote the area of the anastomosis. The circular opaque object is a quarter taped to the side of the animal to allow standardization of measurements. This was located the same distance from the x-ray cassette as the esophagus to compensate for magnification.

termine precisely the gap and tension that a device like the U-clip can traverse. With the use of noninvasive studies, it was possible to follow the size of the esophageal anastomosis over time.

The 9-day-old piglet model proved to be an effective means to quantitate esophageal anastomosis patency over a reproducible growth period. The piglets' esophagus diameters increased by nearly 10-fold during the study period.

The esophagrams were sensitive at quantitating esophageal and anastomotic diameters. They were also sensitive at detecting leaks. The first piglet to receive this procedure had a contained anastomotic leak. It was the opinion of the authors that a residual pneumothorax contributed to this development. This was the reason that chest tubes were left in place on the final 2 piglets.

During the course of the piglets' survival, we found that the anastomoses did not increase in diameter in proportion to the growth of the esophagus. Although this resulted in a relative narrowing, the piglets never had a clinically significant stricture. Based on the esophagram measurements, the anastomoses did not decrease in diameter yet failed to increase in diameter at the same rate as the normal distal esophagus. We expect this was caused by scar formation. It is possible that if the animal was permitted to grow to 100 Kg, the anastomotic diameter may have reached a critical threshold preventing the animal from taking adequate calories by oral diet. However, during the 10-fold increase in piglet size, we observed in this study, this did not occur.

We found that the U-Clips were feasible for use in piglet thoracoscopy for the purpose of creating an esophageal anastomosis. Although nitinol is not an absorbable substance, we noted the disappearance of the U-Clips between the POD 7 and POD 21 films. This finding was confirmed on necropsy. We expect that they were shed into the esophageal lumen and passed through the intestinal tract. Whereas this was not a detriment to the piglets, the U-Clips may not be appropriate for use in applications in which a permanent suture is required.

U-Clips are a feasible alternative to sutures in this piglet model of esophageal reconstruction. U-Clips potentially could reduce the technical difficulty of the procedure in human newborns. This would make the minimally invasive procedure available to a larger population of children.

ACKNOWLEDGMENTS

The authors acknowledge the significant contributions of Carolanne Lovewell and Lori Linn to this work, without whose tireless hours of assistance this report would never have been possible.

REFERENCES

1. Lin PH, Bush RL, Nelson JC, et al: A prospective evaluation of interrupted nitinol surgical clips in arteriovenous fistula for hemodialysis. *Am J Surg* 186:625-630, 2003
2. Wolf RK, Alderman EL, Caskey MP, et al: Clinical and six-month angiographic evaluation of coronary arterial graft interrupted anastomoses by use of a self-closing clip device: A multicenter prospective clinical trial. *J Thorac Cardiovasc Surg* 126:168-178, 2003
3. Rodgers BM, Moazam F, Talbert JL: Thoracoscopy in children. *Ann Surg* 189:176-80, 1979
4. de Campos JR, Andrade Filho LO, Werebe EC, et al: Thoracoscopy in children and adolescents. *Chest* 111:494-497, 1997
5. Rothenberg SS: Thoracoscopy in infants and children. *Semin Pediatr Surg* 3:277-282, 1994
6. Rothenberg SS: Thoracoscopic repair of tracheoesophageal fistula in newborns. *J Pediatr Surg* 37:869-872, 2002
7. Bax KM, van Der Zee DC: Feasibility of thoracoscopic repair of esophageal atresia with distal fistula. *J Pediatr Surg* 37:192-196, 2002
8. Hollands CM, Dixey LN: Robotic-assisted esophagoesophagotomy. *J Pediatr Surg* 37:983-985; discussion 983-985, 2002
9. Kellnar S, Till H, Bohm R, et al: Thoracoscopic surgery of the oesophagus in rats: A training concept for the treatment of tracheoesophageal malformations in preterm infants. *Pediatr Surg Int* 12:116-117, 1997